

# Treatment of open bite with microscREW implant anchorage

Hyo-Sang Park, DDS, MSD, PhD,<sup>a</sup> Tae-Geon Kwon, DDS, MSD, PhD,<sup>b</sup> and Oh-Won Kwon, DDS, MSD, PhD<sup>c</sup>  
Taegu, South Korea

Open bite treatment with microscREW implant anchorage is discussed in relation to vertical control of the posterior dentoalveolar dimension. Maxillary microscREW implants provided anchorage for intruding the posterior teeth and retracting the anterior teeth; mandibular microscREW implants were used to apply intrusion force distal to the mandibular first molars to prevent mesial tipping of the posterior teeth during space closure. Closing the mandibular plane after intruding the maxillary posterior teeth and bodily mesial movement of the mandibular posterior teeth contributed to facial profile improvement. The efficacy and potency of microscREW implants in open bite treatment are discussed. (*Am J Orthod Dentofacial Orthop* 2004;126:627-36)

Open bite malocclusion has long been considered a difficult problem to treat orthodontically because its etiology is complicated and multifactorial.<sup>1,2</sup>

Many treatment modalities to control open bite have been proposed. However, they are not always satisfactory because of the strong relapse tendency, which calls for orthognathic surgery,<sup>3</sup> especially in adults. Dental compensation, such as uprighting the posterior teeth, and uprighting and extruding the anterior teeth, obtainable from multiloop edgewise archwires,<sup>2</sup> can be optional for borderline patients and those who are reluctant to undergo surgery.

Intermaxillary elastics, used in conventional and multiloop edgewise archwire mechanics, usually cause extrusion of the posterior teeth<sup>4,5</sup>; this opens the mandibular plane and has detrimental effects on the facial profile. Therefore, vertical control of the posterior teeth is crucial in the orthodontic treatment of open bite.

Skeletal anchorage, with dental implants,<sup>6</sup> miniplates,<sup>7</sup> miniscrews,<sup>8,9</sup> and microscREWs,<sup>10-13</sup> has been used to provide absolute anchorage. MicroscREW implants are small enough to place in any area of the alveolar bone, easy to place and remove, and

inexpensive. In addition, orthodontic force application can begin almost immediately after placement.<sup>9,11</sup> Therefore, the many advantages have expanded its use to various orthodontic problems.

In managing open bite, skeletal anchorage from miniplates has been reported.<sup>7</sup> The use of microscREW implants, however, has not been discussed. This case report shows the efficiency and simplicity of microscREW implants to control anterior open bite; they provide anchorage to retract the maxillary incisors and control the posterior teeth vertically.

## BIOMECHANICS OF OPEN BITE TREATMENT WITH MICROSCREW IMPLANTS

Although the importance of the axial inclination of the anterior teeth has been widely discussed, the axial inclination of the posterior teeth has not attracted attention. Kim<sup>2</sup> found patients who had normal overbite relationships even with high mandibular plane angles and obtuse gonial angles—ie, long faces. He also found that they have coinciding maxillary and mandibular occlusal planes and upright dentition in relation to the occlusal plane, and emphasized the importance of uprighting the dentition in treating open bite.

Extracting the second molars could minimize resistance to uprighting the posterior teeth in adolescents who have well-shaped and well-positioned third molars. This approach could upright the posterior teeth and establish functional occlusion, thus correcting the open bite; however, the facial profile change was less than desirable, especially in patients who had mild arch length discrepancies or protruding lips. Extracting the premolars should be considered to improve the facial profile. When treating patients

From the College of Dentistry, Kyungpook National University, Taegu, South Korea.

<sup>a</sup>Associate professor, Department of Orthodontics.

<sup>b</sup>Assistant professor, Department of Oral and Maxillofacial Surgery.

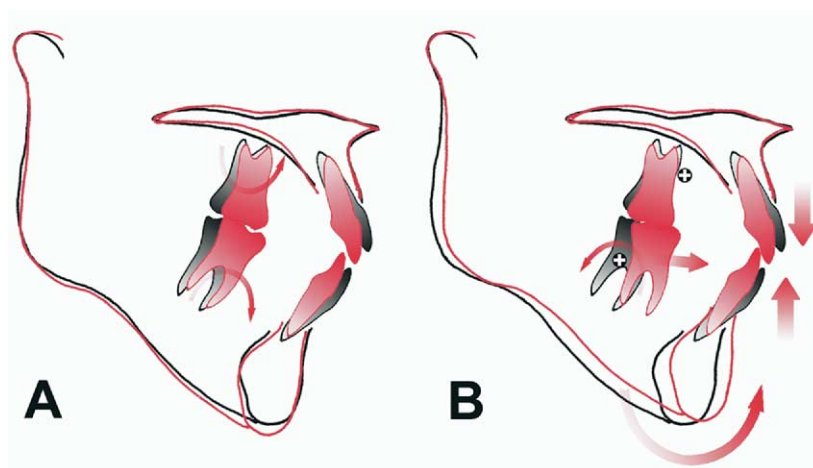
<sup>c</sup>Professor, Department of Orthodontics.

Reprint requests to: Hyo-Sang Park, DDS, MSD, PhD, Department of Orthodontics, College of Dentistry, Kyungpook National University, 101, Dongin-2-Ga, Jung-Gu, Taegu, Korea 700-422; e-mail, parkhs@knu.ac.kr  
Submitted, June 2003; revised and accepted, July 2003.

0889-5406/\$30.00

Copyright © 2004 by the American Association of Orthodontists.

doi:10.1016/j.ajodo.2003.07.019



**Fig 1.** Influence of **A**, extraction of premolars on axial inclination of posterior teeth during space closure, and **B**, microcrew implants to control posterior teeth vertically and retract anterior teeth.

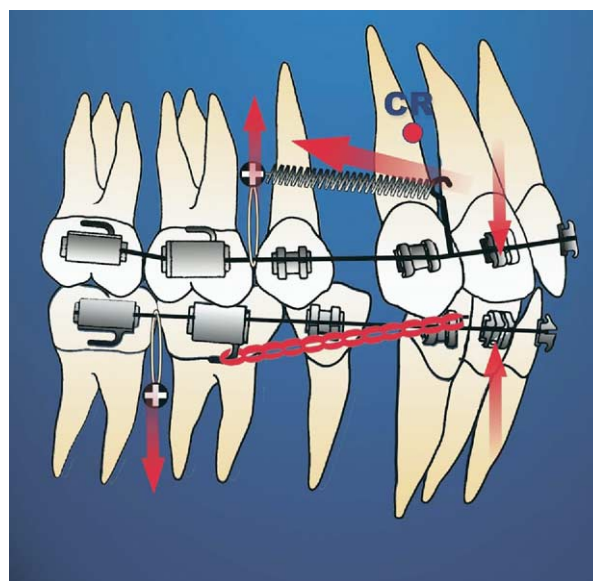
with premolar extractions, the molars tend to tip mesially during space closure; this should be prevented (Fig 1, A).

Microcrew implants, placed between the second premolars and the first molars in the maxillary arch, can provide anchorage for anterior retraction and posterior intrusion of the teeth. Mandibular microcrew implants, placed between the first and second molars, can provide an anchorage for uprighting the molars and counteract the mesial tipping moment during space closure. The mesial movement of the mandibular posterior teeth makes the fulcrum move forward and allows a better chance to close the mandibular plane angle or, at least, prevent opening the mandibular plane angle (Figs 1, B, and 2).

In addition, the use of microcrew implants can eliminate the need for intermaxillary elastics, which have been known to induce extrusion of the molars,<sup>5</sup> and clinicians might have more chance to close the mandibular plane. This can increase the SNB angle and improve the profile.

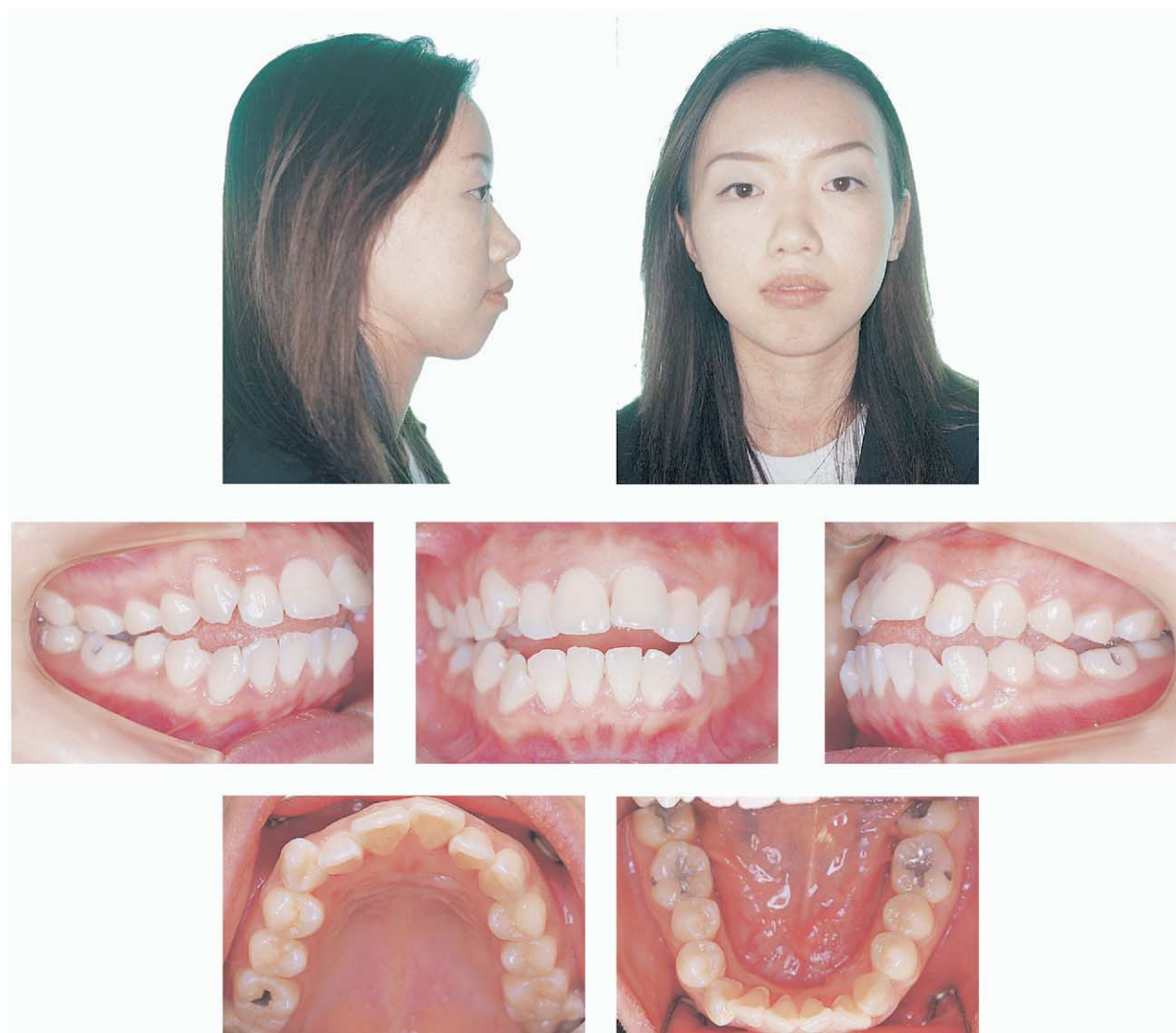## DIAGNOSIS

A 24-year old woman presented with an anterior open bite (Figs 3-5). Her temporomandibular joint showed a slight resorption radiographically, but there were no conspicuous clinical symptoms. The patient had a convex profile caused by a retruded mandible. Cephalometric analysis showed an ANB angle of  $4.5^\circ$  and a mandibular plane angle (FMA) of  $45^\circ$  (Table). She had a large overjet (5 mm) and an anterior open bite ( $-2.5$  mm), and was diagnosed with a skeletal Class II malocclusion with open bite.



**Fig 2.** Schematic illustration of microcrew implant anchorage sliding mechanics for treatment of open bite.

Intraorally, she had Class II relationships on the right side, Class III relationships on the left side, and a posterior crossbite on her left second molars. The posterior teeth showed a considerable mesial inclination, especially at the mandibular first molars, and the only teeth occluded with opposing teeth were the second molars. The arch length discrepancies in the maxillary and mandibular arches were 4.5 and 6 mm, respectively. The dental midline of the maxillary arch was deviated to the left by 1 mm to the skeletal midline, whereas the mandibular one coincided.



**Fig 3.** Pretreatment extraoral and intraoral photographs.

#### **TREATMENT OBJECTIVES**

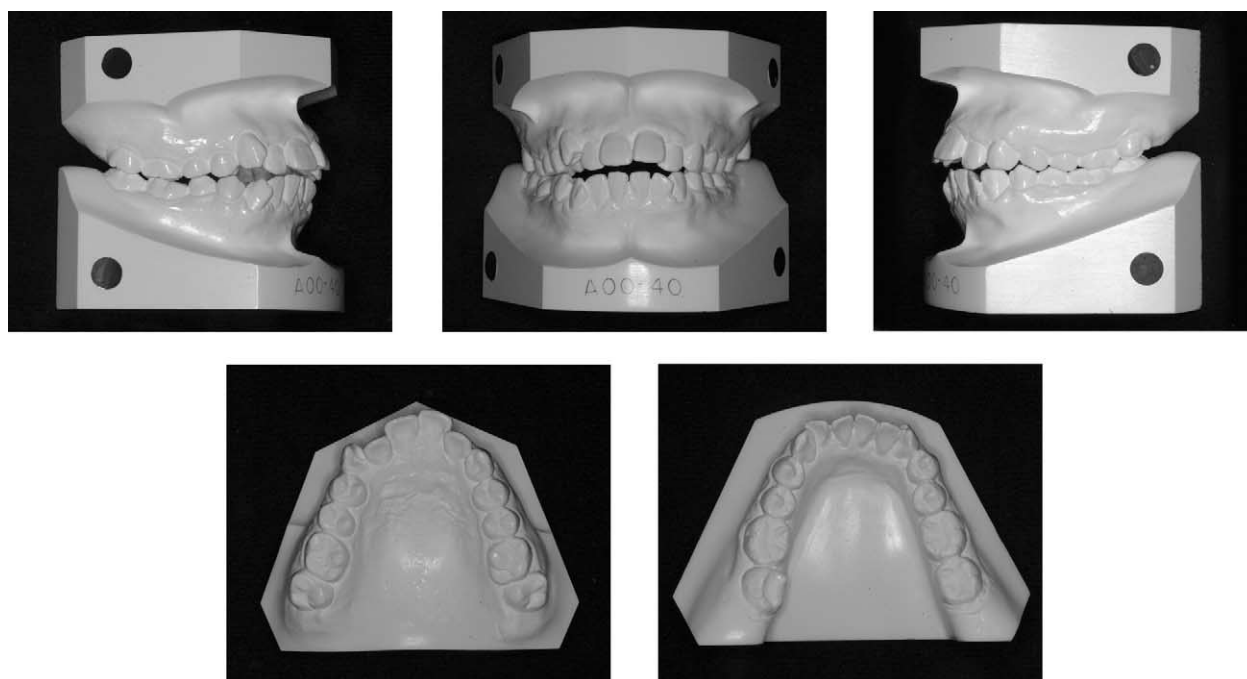
- Resolve crowding in both arches.
- Normalize the overjet and overbite relationships.
- Improve the facial profile.
- Upright the maxillary and mandibular posterior teeth, and establish functional occlusion.
- Correct the crossbite on the left second molars.

#### **TREATMENT ALTERNATIVES**

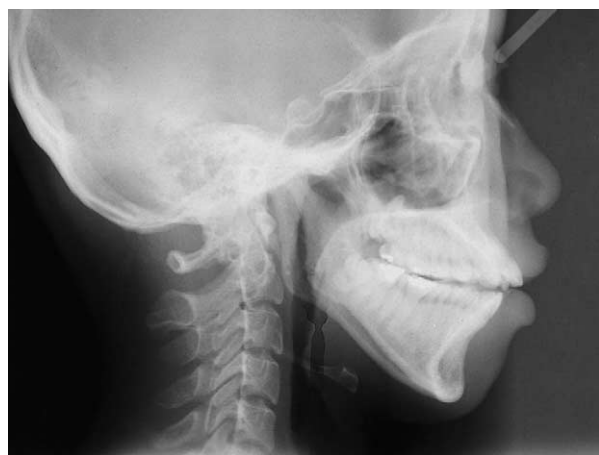The first alternative was orthognathic surgery. In this option, to resolve crowding, the maxillary and mandibular first premolars would be extracted and retracted with moderate anchorage, and the mandibular

incisors would be uprighted. Maxillary posterior impaction, which induces mandibular autorotation, and concurrent mandibular advancement surgery could be performed. Advancing genioplasty would reduce the long lower facial height and move the chin forward. However, the patient rejected orthognathic surgery.

The second alternative was orthodontic treatment with extraction of the maxillary first premolars, the mandibular first premolars on the left side, and the second premolars on the right side. The asymmetric extractions in the mandibular arch would be helpful in correcting molar relationships, because the left side had Class III relationships and the right side had Class II relationships. The difference in the size and shape



**Fig 4.** Pretreatment dental casts.



**Fig 5.** Pretreatment cephalometric radiograph.

between the first and second premolars made this option unfeasible.

The third alternative was extraction of the maxillary first premolars and the mandibular second premolars and microcrew implants for anchorage control. We thought that, by moving the mandibular molars forward after extracting the second premolars, the fulcrum on the terminal molars could be moved forward, thus

**Table.** Cephalometric measurements

	Pretreatment	Posttreatment
SNA(°)	77	77
SNB(°)	72.5	73
ANB(°)	4.5	4
FMA(°)	45	44
PFH/AFH	0.52 (39/75)	0.50 (36/72.5)
FH to Occ P(°)	15.5	17
Ui to FH(°)	119.5	103
IMPA(°)	100.5	85
Z angle(°)	52	60

closing the mandibular plane. By using microcrew implants to control the amount of tooth movement anteroposteriorly in the mandibular arch, we could avoid asymmetric extractions.

After evaluating the expected results and the mandibular response, a decision was made to treat the patient with third alternative. The treatment plan called for extracting the maxillary first premolars to resolve anterior crowding and improve the profile and the mandibular second premolars to move the mandibular posterior teeth forward in hope of moving the fulcrum forward, followed by fixed appliance treatment and microcrew implants for anchorage control.



## TREATMENT PROGRESS

A complete fixed preadjusted edgewise appliance with .022-in slots was attached, and a .014-in nickel-titanium (Ni-Ti) archwire was placed.

Maxillary microscrew implants (8 mm long, 1.2 mm in diameter, Osteomed, Dallas, Tex) were placed into interradicular bone between the maxillary second premolars and the first molars, and mandibular implants (6 mm long, 1.2 mm in diameter, Osteomed) were placed into the cortical bone of the mandibular arch between the first and second molars, as described in previous reports.<sup>11-13</sup>

The microscrew implants were loaded 2 weeks after placement at a force of 150 g. To apply uprighting force to the mesially tipped mandibular first molars, elastic threads were connected from the microscrew implants to the distal end of the archwire. Additionally, the Ni-Ti closing coil spring force was applied from the maxillary microscrew implants to the canine brackets on both sides, retracting the maxillary canine to create enough space to align the anterior teeth. A transpalatal bar was placed to prevent distortion of the arch form and buccoversion of the posterior teeth during intruding force application (Fig 6).

After the maxillary anterior teeth were aligned, a .016 × .022-in stainless steel archwire with anterior hooks was placed, Ni-Ti retraction force was applied from the maxillary microscrew implants, and the 6 anterior teeth were retracted simultaneously. In the mandibular arch, a .017 × .025-in titanium-molybdenum alloy archwire was placed during space closure. Meanwhile, the intruding force was applied to the lower archwire from the mandibular microscrew implants; this was converted to a counterclockwise moment on the first molars and an intruding force on the second molars (Fig 7). These force systems prevented the mandibular molars from tipping mesially, as usually occurs in conventional mechanotherapy.

At 11 months of treatment, the patient's facial profile showed improvement. The intruding force was applied in the maxillary arch in addition to the mandibular arch, by connecting elastic threads from the maxillary microscrew implants to the maxillary archwire (Fig 8). The microscrew implants did not loosen during treatment and were removed by unscrewing them (Fig 9).

## TREATMENT RESULTS

At 23 months of treatment, a well-aligned dentition and a harmonious facial profile were obtained (Figs 10-13). Harmonious facial balance was achieved by retracting the maxillary and mandibular anterior teeth

and closing the mandibular plane after slight intrusion of the maxillary posterior teeth and forward movement of the mandibular posterior teeth with the uprighting. The long lower-lip-to-menton length decreased, and the muscle strain of the mentalis was eliminated. These changes contributed to improvement of the facial profile.

The patient had Class I canine and molar relationships, normal buccal overjet, and a small amount of open bite on the posterior teeth on right side; this had settled at the 1-year retention records (Fig 14). The anterior teeth had normal overjet and overbite relationships, which were maintained during retention.

The initial difference of the lower border of the mandible between the right and left sides disappeared with establishment of the occlusion. Individual occlusal planes, separated from each other initially, were corrected into 1 plane, and all posterior teeth were uprighted to the occlusal planes.

After debonding and debanding, a lingual bonded retainer on the 8 anterior teeth was delivered and stabilized in the mandibular arch, and a wraparound retainer with an anterior clear resin band was prescribed for retention.

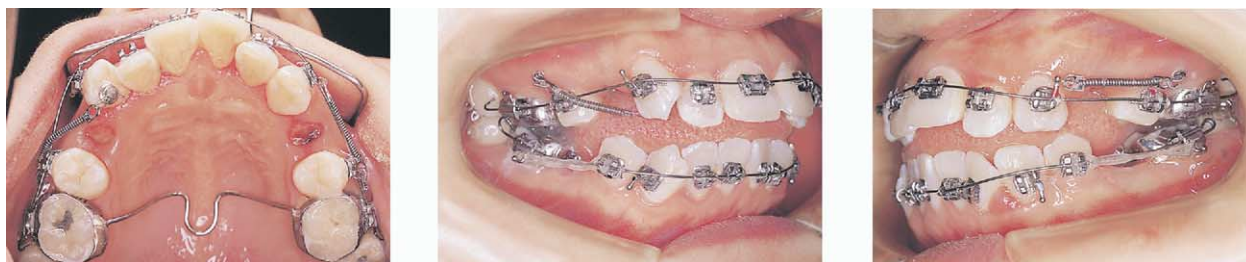On cephalometric superimposition, the maxillary anterior teeth were retracted with intrusion, and the maxillary posterior teeth were intruded and moved distally; the mandibular teeth showed uprighting.

## DISCUSSION

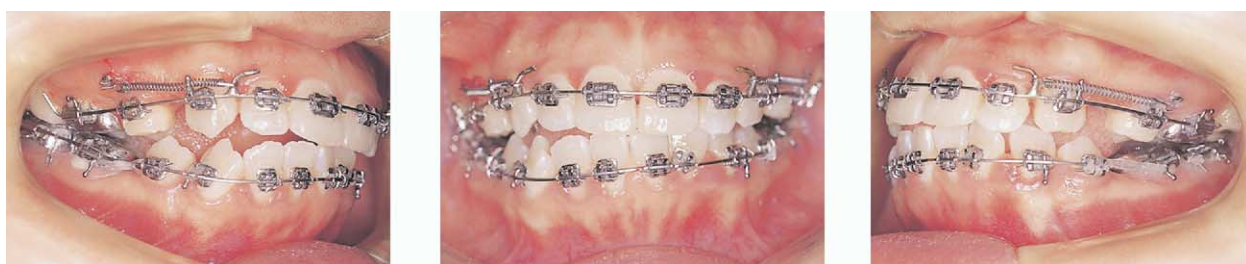In treating open bite, the importance of vertical control of the posterior dentoalveolar height has been extensively discussed.<sup>2,4,14,15</sup> Many clinicians in the Tweed Foundation have emphasized anchorage preparation to prevent extrusion of the mandibular molars; this might be caused by Class II elastics.<sup>14,15</sup> Proper vertical control of the posterior teeth enhanced the mandibular response—in other words, forward mandibular rotation.

Kim<sup>2</sup> stressed the importance of correcting the cants of the occlusal planes and uprighting the posterior teeth against the occlusal plane in managing open bite. A multiloop edgewise archwire has been used to correct open bite with good clinical results. However, anterior vertical elastics can create a vertical extruding force on the anterior teeth and an uprighting force on the posterior teeth, but do not produce sufficient force to distalize the teeth.<sup>5</sup> As a result, the facial profile after treatment can be less than desirable.

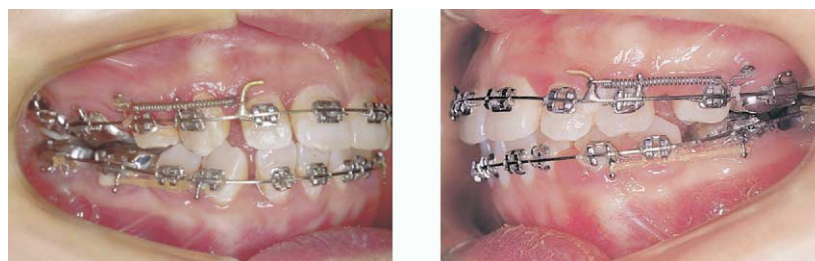To achieve a harmonious facial profile, the anterior teeth should be retracted, in addition to open bite correction by uprighting the posterior teeth and extruding the anterior teeth; therefore, extraction of premolars



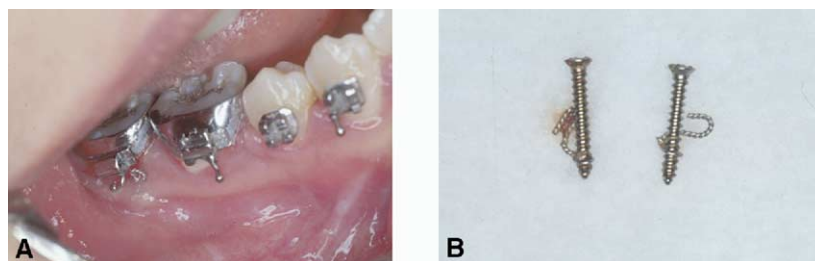
**Fig 6.** Transpalatal bar for maintaining arch form, partial canine retraction, and uprighting intrusion force on mandibular posterior teeth.



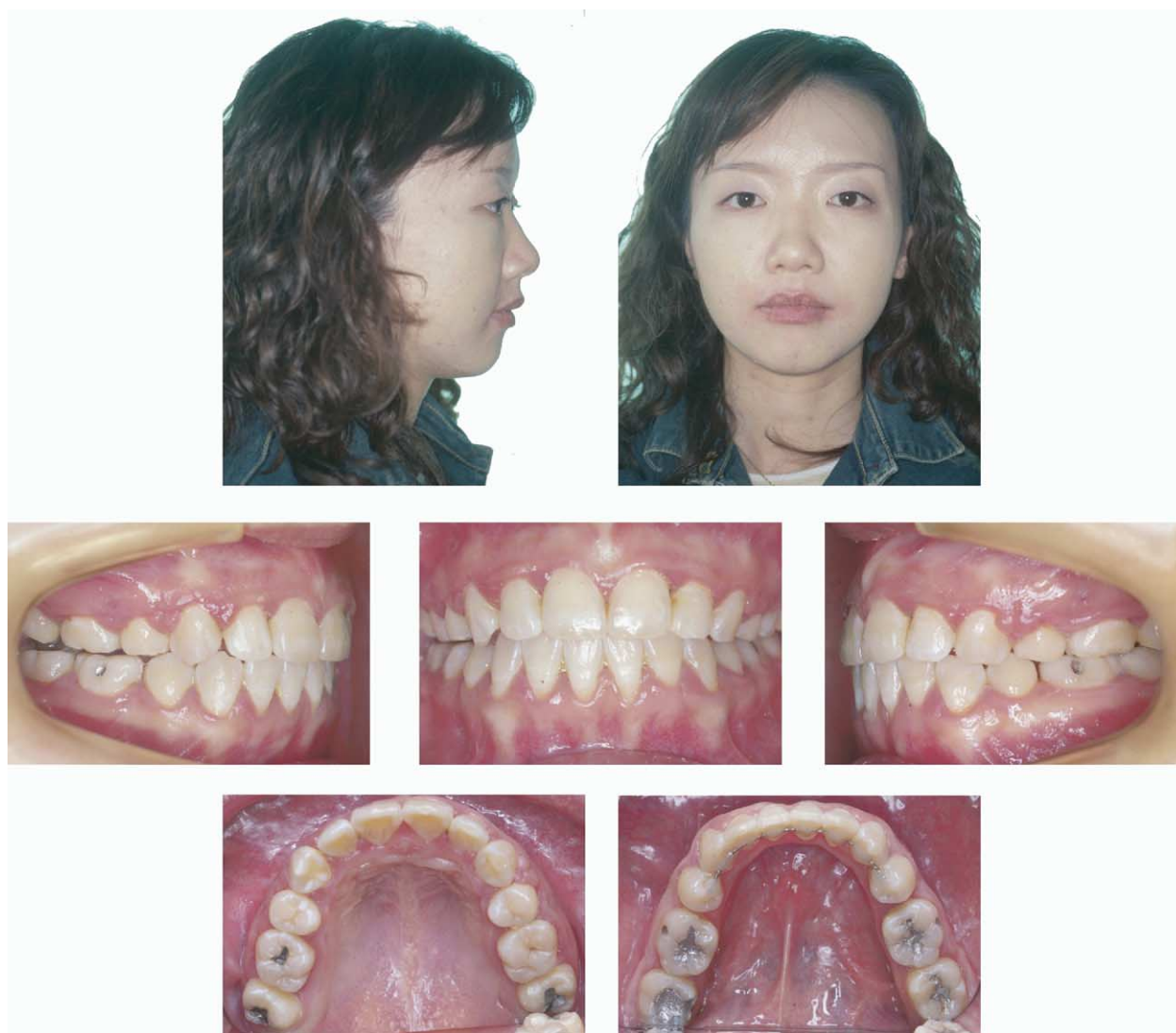**Fig 7.** En masse retraction of 6 maxillary anterior teeth with Ni-Ti coil springs connected from microscREW implants and intrusion force application from microscREW implants to archwire in mandibular arch.



**Fig 8.** Application of intrusion force on maxillary and mandibular posterior teeth.



**Fig 9.** **A**, Wire extension from mandibular microscREW implant, placed midpoint of first and second molars, positioned distal with forward movement of molars. **B**, MicroscREW implants after removal.



**Fig 10.** Posttreatment extraoral and intraoral photographs.

should be considered. As previously mentioned, mesial tipping of the posterior teeth can easily occur with premolar extractions. Therefore, microscrew implants should be used to control the posterior teeth vertically and to retract the anterior teeth.

Microscrew implants have been used to provide anchorage for various types of tooth movements, including intrusion of the anterior and posterior teeth, retraction of the anterior teeth and the whole dentition, protraction of the posterior teeth, and molar uprighting. Their absolute anchorage, small size, and simple and less invasive surgical procedure could increase their clinical use. Most importantly, the small size of micro-screw implants could expand possible locations for

placement, because dental implants need a large amount of bone.

Maxillary microscrew implants were placed into interradicular bone between the second premolars and the first molars. By placing these at 30° to 40° to the long axes of the teeth, not perpendicular to bone surface, the horizontal depth of the embedded micro-screw implants from the bone surface was decreased by 3 mm; the embedded portion would have been 6 mm. Therefore, the apices of the microscrew implants could be placed apart from the root. The thick mandibular cortical bone (3.1-3.2 mm on average<sup>16</sup>) and the 30° to 40° of the placement angle could bear the 6 mm microscrew implants; with 4 mm of the microscrew



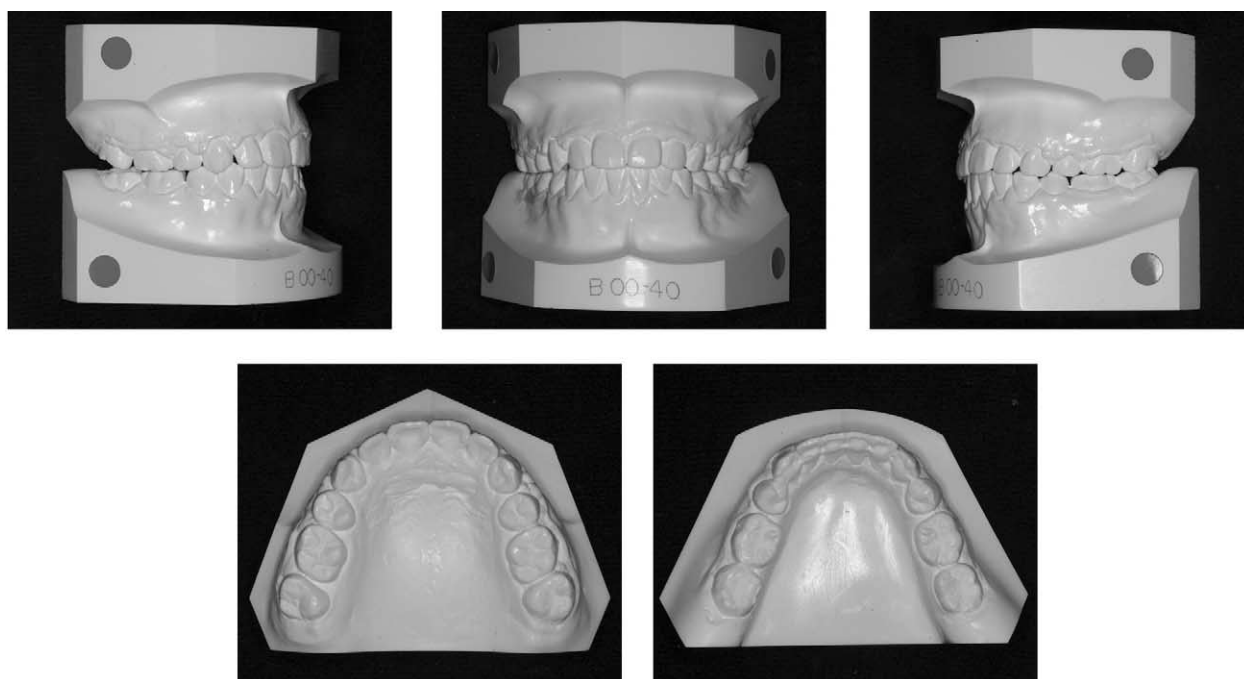


Fig 11. Posttreatment dental casts.

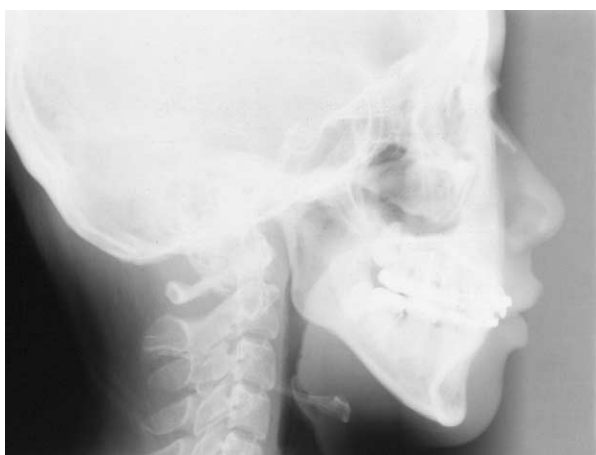

Fig 12. Posttreatment cephalometric radiograph.

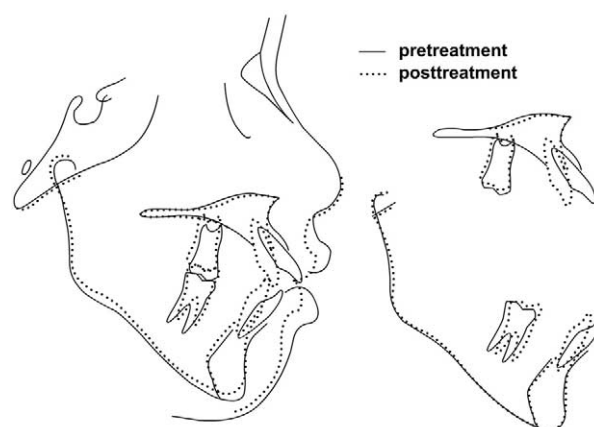


Fig 13. Cephalometric superimposition.

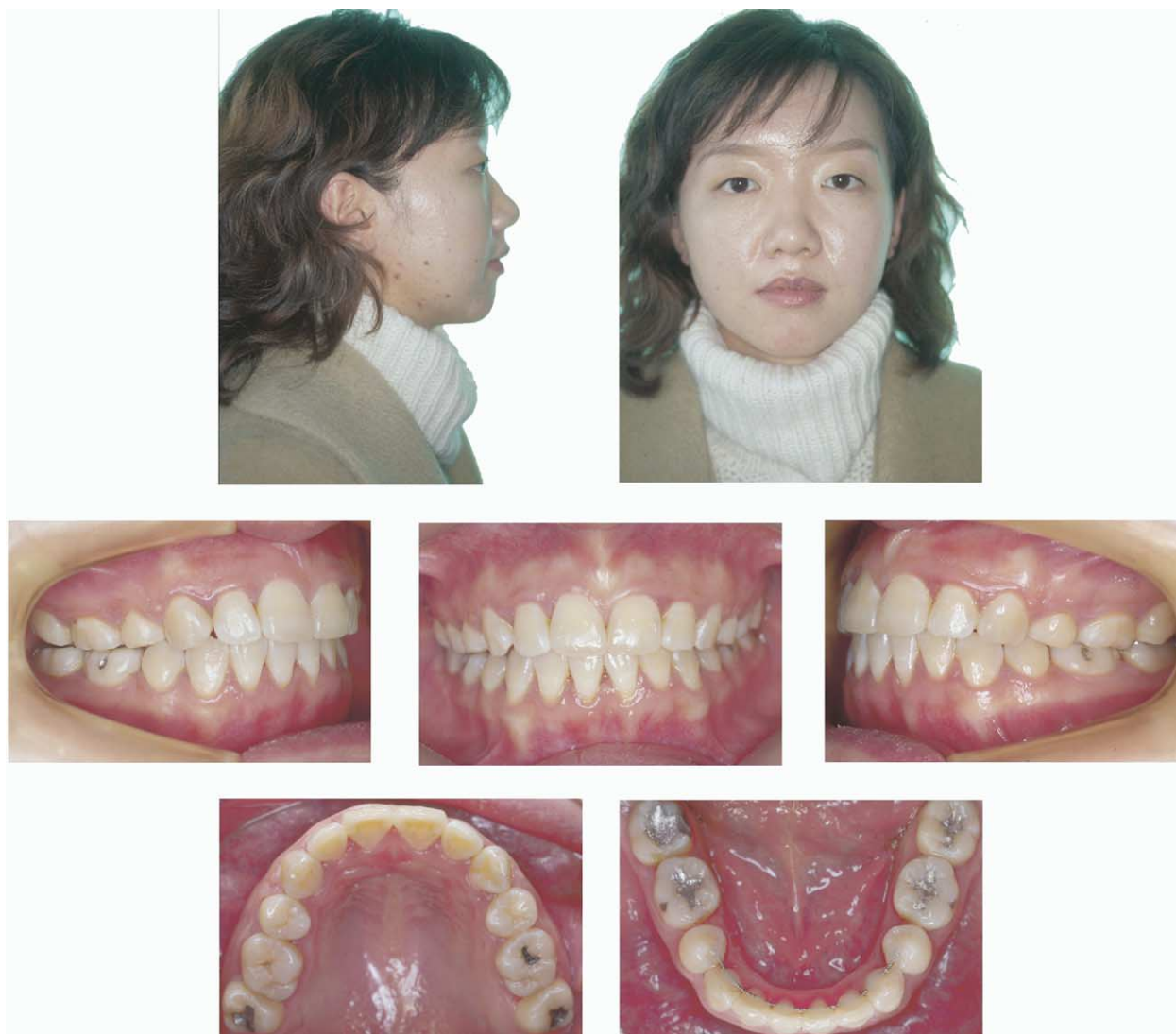implants embedded into the bone, there was no possibility of root damage during placement and tooth movement. During surgical placement, the clinician can feel too much resistance if the microcrew implant touches the root and should place it again with a different angulation to avoid root contact. The small area of damage to the root can be repaired with normal cementum.<sup>17</sup>

In this study, the maxillary posterior teeth, which

act as anchorage in conventional mechanics, showed posterior movement and intrusion during anterior teeth retraction. The 6 anterior teeth could be retracted in the maxillary arch against the microcrew implants without anchorage loss so that the improvement of the facial profile could be obtained in the early phase of treatment, and treatment time could be shortened.

Intrusion force was applied from the mandibular microcrew implants to the mandibular archwire to





**Fig 14.** One-year retention extraoral and intraoral photographs.

prevent mesial tipping of the posterior teeth. The bodily mesial movement of the mandibular posterior teeth without tipping caused the fulcrum to move forward and induced the mandibular plane rotation in a counterclockwise direction, with a concomitant improvement of the facial profile.

By using separate sets of anchorage from micro-screw implants, there was reduced or no need for intermaxillary elastics, which cause extrusion of the posterior teeth and opening of the mandibular plane. Yamaguchi and Nanda<sup>4</sup> noted that intermaxillary elastics caused an increase of the vertical dimension in extraction treatment, but high-pull headgear did not affect the vertical position of the posterior teeth. Re-

duced use of intermaxillary elastics and intrusion of the molars can rotate the mandible in a counterclockwise direction or, at least, maintain the mandibular plane angle.

Assuming that the mesially tipped mandibular posterior teeth would be uprighted by the micro-screw implants, the molar crowns would be moved distally; this would aggravate the Class II relationships on the right side and translate the Class III relationships into Class I relationships on the left side. Extracting the mandibular second premolars seemed to enhance the mesial movement of the posterior teeth to correct the molar occlusion to a Class I relationship.

Microscrew implants can affect the treatment

plan—eg, determining extraction or nonextraction treatment, selecting teeth for extraction, or deciding on orthognathic surgery. Because of their ability to move the whole dentition distally, nonextraction treatment could be increased. Clinicians can conserve healthy first premolars by extracting decayed second premolars, even though extracting the first premolars is necessary to improve the facial profile.

## CONCLUSIONS

Maxillary microscrew implants can provide anchorage for retracting anterior teeth and simultaneously intruding posterior teeth, and mandibular microscrew implants can prevent mesial tipping during space closure. Microscrew implants provide good anchorage to control open bite.

## REFERENCES

1. Speidel TM, Isaacson RJ, Worms FW. Tongue-thrust therapy and anterior dental openbite. *Am J Orthod* 1972;62:287-95.
2. Kim YH. Anterior openbite and its treatment with multiloop edgewise archwire. *Angle Orthod* 1987;57:290-321.
3. Epker BN, Fish LC. Surgical-orthodontic correction of open-bite deformity. *Am J Orthod* 1977;71:278-99.
4. Yamaguchi K, Nanda RS. The effects of extraction and nonextraction treatment on the mandibular position. *Am J Orthod Dentofacial Orthop* 1991;100:443-52.
5. Küçükkelş N, Acar A, Demirkaya, AA, Evrenol B, Enacar A. Cephalometric evaluation of open bite treatment with NiTi archwire and anterior elastics. *Am J Orthod Dentofacial Orthop* 1999;116:555-62.
6. Shapiro PA, Kokich VG. Uses of implants in orthodontics. *Dent Clin North Am* 1988;32:539-50.
7. Umemori M, Sugawara J, Mitani H, Nagasaka H, Kawamura H. Skeletal anchorage system for open bite correction. *Am J Orthod Dentofacial Orthop* 1999;115:166-74.
8. Creekmore TD. The possibility of skeletal anchorage. *J Clin Orthod* 1983;17:266-9.
9. Costa A, Raffini M, Melsen B. Miniscrews as orthodontic anchorage. *Int J Adult Orthod Orthog Surg* 1998;13:201-9.
10. Kanomi R. Mini-implant for orthodontic anchorage. *J Clin Orthod* 1997;31:763-7.
11. Park HS, Bae SM, Kyung HM, Sung JH. Micro-implant anchorage for treatment of skeletal Class I bialveolar protrusion. *J Clin Orthod* 2001;35: 417-22.
12. Park HS. Intrusion molar con anclaje de microimplantes (MIA, micro-implants anchorage). *Orthodoncia Clinica* 2003;6:31-6.
13. Park HS, Kyung HM, Sung JH. A simple method of molar uprighting with micro-implant anchorage. *J Clin Orthod* 2002; 36:592-6.
14. Klontz HA. Facial balance and harmony: an attainable objective for the patient with a high mandibular plane angle. *Am J Orthod Dentofacial Orthop* 1998;114:176-88.
15. Lamarque S. The importance of occlusal plane control during orthodontic mechanotherapy. *Am J Orthod Dentofacial Orthop* 1995;107:548-58.
16. Champy M, Pape H, Gerlach KL, Lodde JP. Mandibular fracture. In: Kruger E, Schilli W editors. *Oral and maxillofacial traumatology*. Vol 2. Chicago, London, Berlin, Rio de Janeiro, Tokyo: Quintessence; 1986. p. 19-43.
17. Tsukikochi, M. Autotransplantation of teeth. Tokyo: Quintessence; 1999. p. 29.